BALKAN ORL-HNS

ORIGINAL ARTICLE
BALKAN ORL-HNS 2026; 3: 1-7

Effect of Conventional Versus Microsaw Osteotomy Techniques on Postoperative Patient Comfort in Septorhinoplasty

ABSTRACT

Background: Septorhinoplasty often causes early periorbital edema, ecchymosis, and pain that may impair patient comfort. This study compared conventional and powered microsaw osteotomy techniques in terms of early postoperative morbidity and patient satisfaction.

Methods: In this prospective randomized single-center study, 60 patients undergoing open septorhinoplasty were allocated to conventional osteotomy (n = 30) or microsaw osteotomy (n = 30). Apart from the osteotomy instrument, all operative steps and postoperative care were standardized. Edema and ecchymosis were graded on postoperative days 3 and 7 by 2 blinded surgeons. Pain was recorded using a visual analog scale on postoperative days 1, 3, and 7, and patient satisfaction was rated on day 7.

Results: The groups were similar in age and sex ($P > .05$). No significant between-group differences were found in edema or ecchymosis on postoperative days 3 or 7 (all $P > .05$), although both parameters improved significantly within each group over time. Pain scores decreased significantly from postoperative day 1 to day 7 in both groups, with no significant between-group differences at any time point (day 1, $P = .547$; day 3, $P = .212$; day 7, $P = .497$). Day-7 satisfaction scores were also similar (5.06 ± 1.74 vs 5.33 ± 1.62; $P = .542$).

Conclusion: Powered microsaw osteotomy did not improve early postoperative patient comfort compared with conventional osteotomy. Meticulous surgical technique may be more important than instrument choice in limiting early morbidity after septorhinoplasty.

Keywords: Ecchymosis, edema, osteotomy, pain, patient satisfaction, postoperative, rhinoplasty

Introduction

Septorhinoplasty is widely performed to address nasal septal deformities and refine external nasal form, with the overarching goal of achieving both functional nasal breathing and harmonious facial aesthetics.[1] Despite these objectives, the early postoperative period commonly involves periorbital ecchymosis, edema, and pain, which can substantially affect short-term patient comfort and early satisfaction.[2] Accordingly, multiple strategies have been evaluated to mitigate these morbidities, including perioperative corticosteroid protocols[3] and technical modifications of osteotomy approaches such as internal versus external methods.[4]

Controlled osteotomy of the nasal bones remains a critical component of many rhinoplasty procedures.[5] Osteotomies permit mobilization and repositioning of the bony vault to correct

Copyright @ Author(s) - Available online at https://balkanorl-hns.org/EN.
Content of this journal is licensed under a Creative Commons Attribution-NonCommercial 4.0 International License.

Sedat Rüzgar[1]
Ufuk Düzenli[2]
Yunus Emre Topan[3]
Alper Tabaru[2]

[1]*Department of Otolaryngology, Gelişim University, İstanbul, Türkiye*
[2]*Department of Otolaryngology, Van Training and Research Hospital, Van, Türkiye*
[3]*Department of Otolaryngology, Uşak University Medical Faculty, Uşak, Türkiye*

Corresponding author:
Alper Tabaru
✉ alpertabaru@gmail.com

Received: March 06, 2026
Accepted: April 17, 2026
Publication Date: July 20, 2026

Cite this article as: Rüzgar S, Düzenli U, Topan YE, Tabaru A. Effect of conventional versus microsaw osteotomy techniques on postoperative patient comfort in septorhinoplasty. *Balkan ORL-HNS.* 2026, 3, 0144, doi: 10.5152/bohns.2026.25144.

DOI: 10.5152/bohns.2026.25144

asymmetry and narrow the nasal pyramid.[6] Conventional techniques typically rely on guarded osteotomes with mallet-assisted lateral osteotomies, sometimes combined with saw-based transverse osteotomies, to achieve the desired fracture pattern.[7] However, even when effective, these maneuvers may contribute to soft-tissue trauma and subsequent bruising and swelling.[5-7]

In response, alternative osteotomy technologies intended to reduce collateral tissue injury have gained attention.[8] Piezoelectric ultrasonic osteotomy has been extensively studied, with several reports describing reduced early postoperative edema and ecchymosis compared with conventional techniques.[9-11] Nonetheless, outcomes across studies are variable, and practical limitations as well as potential soft-tissue effects under certain conditions have also been reported.[7,12]

Another instrument increasingly discussed for rhinoplasty osteotomies is the oscillating microsaw.[13] Technical descriptions emphasize its capacity to create thin, controlled bony cuts with less applied force, typically combined with soft-tissue protection (guard/retractor) and irrigation to limit thermal effects.[14] Although these characteristics have been proposed to improve early postoperative comfort,[15] comparative clinical evidence remains less extensive than for piezoelectric systems.

Therefore, the present prospective randomized study compared conventional osteotomy instruments with a powered oscillating microsaw in open septorhinoplasty, focusing on early patient-centered outcomes: postoperative edema, ecchymosis, pain, and patient satisfaction. The authors hypothesized that microsaw-assisted osteotomy might be associated with improved early recovery outcomes relative to conventional instruments.

Material and Methods

Study Design and Patients

Eligible participants were prospectively recruited at a single center between November 1, 2019, and November 30, 2023. The study protocol was approved by the Van Yüzüncü Yıl University Faculty of Medicine Clinical Research Ethics Committee (Approval No.: 07; Date: April 17, 2019). Sixty patients who were scheduled to undergo primary septorhinoplasty for functional and aesthetic indications were enrolled. Patients were randomly assigned (1:1) into 2 groups of 30, corresponding to the osteotomy technique used during their surgery. Group 1 (conventional osteotomy) consisted of 30 patients who underwent nasal osteotomies using standard instruments, and Group 2 (microsaw osteotomy) consisted of 30 patients in whom osteotomies were performed with a powered microsaw device. Randomization was achieved by simple random assignment as patients were recruited, without any stratification or selection criteria regarding age, sex, or nasal deformity characteristics. Patients with prior nasal surgery, those requiring only tip-plasty (no osteotomies) or those with coagulopathies were excluded to maintain a homogeneous sample. All participants provided written informed consent.

Surgical Techniques

All surgeries were performed by the same surgical team under general anesthesia with endotracheal intubation. A standard open technique septorhinoplasty was carried out in each case. After infiltration of the nasal dorsum and septum with a local anesthetic solution containing epinephrine for vasoconstriction, a transcolumellar incision (Goodman incision) was made, and the nasal soft tissue envelope was elevated in the subperiosteal and subperichondrial planes. The bony and cartilaginous framework of the nose was thus exposed, extending laterally to the nasal bone–maxillary junction (medial canthus level) and superiorly to the nasal radix.

The dorsal hump (if present) was removed using conventional techniques (osteotome or rasp) as needed, and septoplasty or spreader graft placement was performed for middle vault reconstruction when indicated. Tip reshaping maneuvers (e.g., cephalic trim of lower lateral cartilages, sutures, grafts) were then completed prior to osteotomy.

For the nasal bone osteotomies, different instruments were used in each group:

Group 1—Conventional Osteotomy: Lateral osteotomies were performed using a 3-mm guarded straight osteotome (a traditional sharp chisel) applied percutaneously at the pyriform aperture on each side. Gentle, incremental taps with a mallet were used to create controlled greenstick fractures along the lateral nasal walls. For the transverse osteotomy (at the nasal root), a fine surgical saw (Taştan-Çakır nasal saw, Medisoft, Türkiye) was used by hand to connect the lateral osteotomies across the nasal bridge. This low-to-low osteotomy technique is the classic approach to mobilize the nasal bones.

Group 2—Microsaw Osteotomy: In this group, osteotomies were executed using a powered microsaw device driven by a micromotor (Nouvag AG, Goldach, Switzerland). An oscillating microsaw blade was utilized to perform the transverse osteotomy at the nasal radix, and narrow reciprocating (oscillating) saw blades (sometimes called "compass saws") were used intranasally or percutaneously for the lateral osteotomies. The microsaw's high-frequency oscillation allowed the bone cuts to be made with a slicing motion rather than a fracturing impact. A protective retractor was placed under the soft tissues during sawing to prevent injury to the periosteum, mucosa, and skin. Continuous saline irrigation was applied during sawing to avoid heat buildup in the bone. The goal was to achieve the same osteotomy lines as in the conventional technique, but with potentially less mechanical trauma to surrounding tissues.

Upon completion of osteotomies, the nasal bones were infractured (medially mobilized) in a controlled manner to close the open roof created by hump removal (when applicable) and to narrow the bony vault. Care was taken in both groups to minimize periosteal stripping and mucosal tears. Finally, the incisions were closed and the nose was immobilized with internal nasal splints (as needed for septal support) and an external dorsal splint. Standard postoperative care (head elevation, cold compresses in the first 24-48 hours, and analgesics)

MAIN POINTS

- *This prospective randomized study compared conventional and powered microsaw osteotomy in 60 septorhinoplasty patients.*
- *Microsaw osteotomy did not reduce early postoperative edema, ecchymosis, or pain compared with conventional osteotomy.*
- *Early patient satisfaction at postoperative day 7 was similar between the 2 techniques.*
- *When osteotomies are performed meticulously, surgical technique may influence short-term comfort more than instrument choice.*

was applied uniformly to all patients. No perioperative steroids were administered beyond the local anesthetic epinephrine mixture.

Outcome Measures

The primary outcomes of interest were patient comfort indicators in the early postoperative period: edema, ecchymosis, pain, and patient satisfaction.

Edema and Ecchymosis Assessment: Postoperative periorbital edema (swelling of the eyelids) and ecchymosis (bruising around the eyes) were evaluated on postoperative day 3 and day 7. Two independent evaluating surgeons (observers) assessed each patient's photographs or in-person appearance at those time points. Importantly, these observers were blinded to which osteotomy technique had been used for each patient, to reduce bias in evaluation. A graded scale was used for each parameter based on previously described criteria in rhinoplasty literature. Edema was graded on a 4-point scale: 1 = minimal/no swelling (no eyelid edema obscuring the iris), 2 = mild swelling (partial coverage of the iris by swollen eyelids), 3 = moderate swelling (swollen eyelids fully covering the iris), and 4 = severe swelling (eyes completely swollen shut). Ecchymosis was graded on a 3-point scale: 1 = bruising limited to the medial one-third of the lower and/or upper eyelids, 2 = bruising extending to the medial two-thirds of the eyelids, and 3 = bruising involving the entire length of one or both eyelids. The higher the score, the more severe the swelling or bruising. The edema and ecchymosis scores from both observers were recorded separately for analysis, to allow assessment of inter-observer consistency.

Pain Assessment: Postoperative pain was self-assessed by patients using a numerical visual analog scale (VAS) ranging from 1 to 10, where 1 represented no pain and 10 represented the worst imaginable pain. Patients recorded their pain score at postoperative day 1, day 3, and day 7, reflecting the typical early recovery interval. They were instructed to specifically rate pain related to the nasal surgery (excluding any unrelated discomfort).

Patient Satisfaction: Early patient satisfaction was gauged on postoperative day 7, once the initial acute recovery phase had passed and before the removal of the external nasal splint (which typically occurs around day 7 in the practice). Patients were asked to rate their overall satisfaction with the surgical outcome and their recovery up to that point on a scale from 1 to 10, where 1 indicated "extremely dissatisfied" (or worst possible outcome) and 10 indicated "extremely satisfied" (or best possible outcome). This single-question satisfaction score captures the patient's subjective assessment of results and comfort in the first week.

Statistical Analysis

All data were compiled and analyzed using SPSS, version 16.0 (SPSS Inc.; Chicago, IL, USA). Descriptive statistics were calculated for each variable. Continuous variables (e.g., age, pain scores, satisfaction scores) are reported as mean ± standard deviation. Categorical variables (e.g., sex distribution) are reported as counts or percentages.

Between-group comparisons of continuous variables (such as mean edema, ecchymosis, pain, and satisfaction scores) were performed using the independent samples *t*-test, given that data approximated a normal distribution. For categorical data like sex, the chi-square test was used to compare proportions between groups. Within-group comparisons of repeated measures over time (e.g., pain scores on day 1 vs day 3 vs day 7 or edema scores on day 3 vs day 7) were analyzed using paired *t*-tests. Inter-observer agreement on edema and ecchymosis scoring was evaluated by calculating the intraclass correlation coefficient (ICC) for the 2 sets of ratings; a high degree of concordance would indicate reliability of the observational assessments. A *P* value less than .05 was considered statistically significant for all analyses.

Results

Patient Demographics

A total of 60 patients were included and completed the study (no dropouts or exclusions after randomization). Group 1 (conventional osteotomy, n = 30) consisted of 26 females and 4 males, while Group 2 (microsaw osteotomy, n = 30) had 21 females and 9 males. The sex distribution did not significantly differ between the 2 groups (chi-square, $P = .209$), indicating successful randomization without bias in gender (Table 1). The mean age of patients in Group 1 was 24.10 ± 4.83 years, and in Group 2, it was 25.53 ± 6.08 years, which was not a statistically significant difference ($P = .316$). Thus, the 2 cohorts were demographically similar.

Edema and Ecchymosis Outcomes

Early postoperative periorbital edema and ecchymosis scores for Group 1 and Group 2 on day 3 and day 7 are presented in Table 2. The evaluations from the 2 blinded observers were in close agreement. Inter-observer reliability was high; there were no significant systematic differences between the 2 raters' scores (the intraclass correlation for scoring was significant, indicating consistency). For simplicity, Table 2 presents the mean scores as evaluated by each observer, and statistical analysis was applied to each observer's dataset as well as to the combined data.

On postoperative day 3, the average edema score in Group 1 was approximately 2.8 (on the 1-4 scale), and in Group 2, it was about 2.7, with no significant difference between the groups ($P > .5$ for both observers' assessments). By postoperative day 7, edema had substantially decreased in both groups (mean scores around 1.6 in Group 1 and 1.5 in Group 2). There was no statistically significant difference in day 7 edema severity between Group 1 and Group 2 ($P > .4$)—both techniques yielded similar mild edema by day 7. Within each group, edema scores improved significantly from day 3 to day 7 ($P < .01$ in both groups), reflecting the expected natural resolution of swelling over time.

Similarly, ecchymosis (bruising) scores on day 3 showed moderate bruising in both groups (mean scores ~2.2-2.4 on the 1-3 scale for extent of bruising). There was no significant difference between the conventional and microsaw groups in the extent of bruising on day 3 ($P = .09$ and $P = .31$ for observer 1 and 2, respectively; both > .05). By day 7, ecchymosis had greatly improved, with mean scores around

Table 1. Baseline Demographic Characteristics of the Study Groups

Variable	Conventional Osteotomy (n = 30)	Microsaw Osteotomy (n = 30)	*P*
Age, years (mean ± SD)	24.10 ± 4.83	25.53 ± 6.08	.316
Sex (female/male), n	26/4	21/9	.209
Sex (female), n (%)	26 (86.7)	21 (70.0)	-
Sex (male), n (%)	4 (13.3)	9 (30.0)	-

Data are presented as mean ± SD or n (%). *P* values were calculated using the independent samples *t*-test for age and the chi-square test for sex distribution.

Table 2. Early Postoperative Edema and Ecchymosis Scores Assessed by 2 Blinded Observers

Outcome (Scale)/ Timepoint	Conventional Obs 1 (Mean ± SD)	Conventional Obs 2 (Mean ± SD)	Microsaw Obs 1 (Mean ± SD)	Microsaw Obs 2 (Mean ± SD)	*P* (Between Groups) Obs 1	*P* (Between Groups) Obs 2	ICC (Obs1 vs Obs2) (*P* value)	Within-Group *P* Day 3 vs Day 7 Conventional	Within-Group *P* Day 3 vs Day 7 Microsaw
Edema (1-4) POD 3	2.83 ± 0.64	2.76 ± 0.62	2.73 ± 0.63	2.70 ± 0.65	.550	.688	.787 (.001)	-	-
Edema (1-4) POD 7	1.63 ± 0.49	1.60 ± 0.49	1.53 ± 0.50	1.56 ± 0.49	.795	.441	.793 (.001)	.001	.002
Ecchymosis (1-3) POD 3	2.40 ± 0.49	2.20 ± 0.55	2.20 ± 0.20	2.06 ± 0.44	.094	.309	.822 (.001)	-	-
Ecchymosis (1-3) POD 7	1.36 ± 0.49	1.40 ± 0.49	1.30 ± 0.46	1.26 ± 0.44	.581	.291	.885 (.001)	.001	.002

POD= postoperative day. Observer (Obs) 1 and 2 were blinded assessors. Between-group *P*values compare conventional vs microsaw at the same timepoint (independent samples *t*-test). Within-group *P* values compare POD 3 vs POD 7 within each group (paired *t*-test).
ICC, intraclass correlation coefficient for inter-observer agreement; POD, postoperative day.

1.3-1.4 in both groups (indicating only mild residual bruising or none in many patients). There was no significant intergroup difference in ecchymosis on day 7 ($P > .2$ for both observers' ratings). The reduction in ecchymosis from day 3 to day 7 was statistically significant within each group ($P < .01$), mirroring the clinical resolution of bruising over the first week after surgery.

Overall, the use of a microsaw did not measurably reduce early postoperative swelling or bruising compared to the conventional osteotomy technique. Table 2 confirms that at both evaluated time points (3 and 7 days post-op), edema and ecchymosis outcomes were equivalent in the 2 groups. The natural postoperative course of decreasing edema and ecchymosis over time was observed in both cohorts, and careful surgical technique in both methods likely kept these trauma indicators to moderate levels initially and mild levels by 1 week.

Pain Scores

Postoperative pain levels reported by patients in each group are shown in Table 3 and the trend over time is illustrated in Figure 1. On postoperative day 1, patients in Group 1 reported a mean pain score of 4.20 ± 1.27 (on the 1-10 scale), whereas Group 2 reported a mean pain score of 4.00 ± 1.28. These scores correspond to a mild-to-moderate level of pain in the immediate recovery period. There was no statistically significant difference in day 1 pain between the 2 groups ($P = .547$). By day 3, mean pain scores had decreased to 2.03 ± 0.66 in Group 1 and 1.80 ± 0.76 in Group 2, as the acute pain from surgery subsided. Again, the difference between groups was not significant ($P = .212$). By day 7, pain was minimal in both groups, with mean scores of 1.20 ± 0.40 for Group 1 and 1.13 ± 0.34 for Group 2 (no significant difference, $P = .497$).

Thus, at each postoperative time point assessed (days 1, 3, and 7), patients who underwent conventional osteotomy and those who underwent microsaw osteotomy reported similar pain levels. Importantly, both groups experienced a significant reduction in pain over time. Paired comparisons show that pain scores in each group improved from day 1 to day 3 ($P < .001$) and further from day 3 to day 7 ($P < .001$ for within-group comparisons). This time-dependent improvement is expected as part of the healing process, but it also indicates that neither technique caused prolonged pain relative to the other. The parallel downward trajectories of the pain curves for Group 1 and Group 2 (as depicted in Figure 1) underscore that the choice of osteotomy instrument did not significantly alter the pain experienced in the first postoperative week.

Patient Satisfaction

Early postoperative satisfaction ratings (on day 7) are summarized in Table 4. Group 1 patients had a mean satisfaction score of 5.06 ± 1.74 (out of 10) regarding their surgical outcome and overall experience up to that point, whereas Group 2 patients had a mean satisfaction score of 5.33 ± 1.62. These values indicate a moderate level of satisfaction in both groups 1 week after surgery, which is understandable given that final aesthetic outcomes are not yet evident and some discomfort and swelling persist at 1 week. The comparison of satisfaction scores between the 2 groups showed no statistically significant difference ($P = .542$). In other words, patients who underwent microsaw osteotomies were not notably more satisfied (nor less satisfied) than those who had conventional osteotomies in the early postoperative period.

The authors also observed that the satisfaction scores did not strongly correlate with the minor differences in edema or ecchymosis between

Table 3. Postoperative Pain Scores (1-10 scale) at Postoperative Days 1, 3, and 7

Timepoint	Conventional Osteotomy (n = 30) (Mean ± SD)	Microsaw Osteotomy (n = 30) (Mean ± SD)	*P* (Between Groups)
POD 1	4.20 ± 1.27	4.00 ± 1.28	.547
POD 3	2.03 ± 0.66	1.80 ± 0.76	.212
POD 7	1.20 ± 0.40	1.13 ± 0.34	.497

Pain was self-assessed on a 1-10 scale (1 = no pain; 10 = worst imaginable pain).
POD, postoperative day.

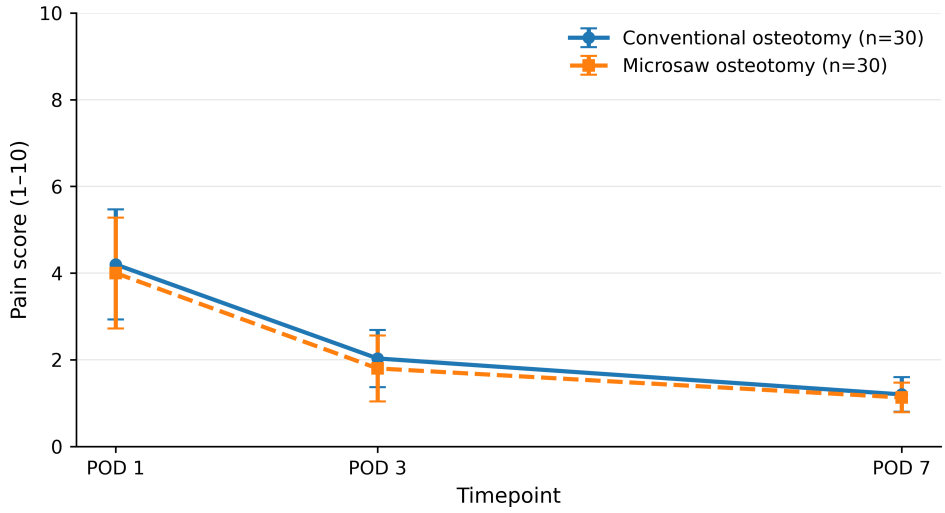

Figure 1. Postoperative pain trend: Line graph depicting the mean pain scores (VAS, 1-10) on postoperative day 1, day 3, and day 7 for Group 1 (Conventional) and Group 2 (Microsaw). Both groups show a similar declining trend in pain over time, with no significant difference between the groups at any time point. VAS, Visual Analog Scale.

patients, likely because those differences were minimal. Most patients in both groups expressed a fair level of contentment with their recovery by day 7, and there was considerable individual variability in satisfaction unrelated to the osteotomy method. No patient in either group reported severe dissatisfaction at the one-week follow-up; even those with higher degrees of bruising or swelling still gave moderate satisfaction scores, perhaps reflecting effective pain control and adequate preoperative counseling about expected postoperative symptoms.

Discussion

This study examined whether using a powered oscillating microsaw for nasal osteotomies would improve early postoperative recovery and comfort in septorhinoplasty patients compared to the traditional osteotomy tools. The principal finding is that there was no significant difference between the microsaw and conventional osteotomy techniques in terms of early postoperative edema, ecchymosis, pain, or patient satisfaction. Both groups of patients had similar levels of swelling and bruising around the eyes in the first week, experienced comparable trajectories of pain resolution, and reported analogous satisfaction with their surgical outcomes at 1 week post-op. These results suggest that the microsaw, despite its theoretical advantages in precision and reduced tissue trauma, did not confer a clear clinical benefit over well-executed conventional osteotomies in the context of early patient-centered outcomes.

It is important to contextualize these findings within the existing body of literature. Piezoelectric osteotomy devices have been a prominent focus of recent research. Multiple studies have demonstrated reductions in early postoperative edema and ecchymosis with piezo instruments relative to the hammer-and-chisel method.[4,5,8,11] For instance, Ilhan et al[9] found that patients treated with ultrasonic (piezo) osteotomies had significantly less bruising and swelling at days 3 and 7 than those with conventional osteotomies. Another study by Fallahi et al[16] reported not only reduced ecchymosis and edema but also lower pain scores in a piezo group versus a traditional osteotomy group. Piezoelectric cutting is thought to spare soft tissue due to its selective effect on mineralized structures and minimal scatter of vibrational energy, which can translate to a gentler postoperative course.[17] However, piezosurgery is not without drawbacks: it can be time-consuming, expensive, and, as Demirbilek pointed out, it is not entirely benign to soft tissues—their work noted potential damage from vibration, especially in patients with thin, delicate nasal skin.[12] Furthermore, not all studies have found dramatic differences; Taskin et al[7] observed no significant difference in swelling or bruising when

Table 4. Early Postoperative Patient Satisfaction Score (Postoperative Day 7)

Variable	Conventional Osteotomy (n = 30) (Mean ± SD)	Microsaw Osteotomy (n = 30) (Mean ± SD)	*P* (Between Groups)
Satisfaction score	5.06 ± 1.74	5.33 ± 1.62	.542

Satisfaction was self-rated on a 1-10 scale (1 = extremely dissatisfied; 10 = extremely satisfied).

comparing piezoelectric lateral osteotomy to a conventional 2-mm osteotome, suggesting that surgical technique and other factors can modulate outcomes.

In contrast to piezo devices, the oscillating microsaw has not been studied as extensively. Avşar described his experience with the microsaw and advocated its safety and efficacy in rhinoplasty osteotomies.[14] The microsaw's ultrathin blade and oscillating action enable precise nasal bone cuts and may require less force than mallet-assisted osteotome techniques, potentially limiting collateral tissue trauma.[13] The built-in guard, together with the use of a protective retractor, is intended to shield adjacent soft tissues (nasal mucosa, periosteum, and skin), while continuous irrigation helps limit heat generation.[18] Avşar also reported narrow osteotomy lines with rapid healing and suggested that this approach could reduce postoperative edema and bruising.[14] However, in this study, the authors did not observe an improvement in these outcomes. One explanation may be that the conventional technique in the study was optimized to minimize trauma: the osteotome used for lateral cuts was narrow and guarded, and transverse cuts were performed with a fine saw rather than relying on greenstick fracture. This controlled approach likely reduced excessive bone fragmentation and soft tissue injury. Consistent with this, edema and ecchymosis in the conventional group were moderate and comparable to rates reported in piezo or microsaw series.[4] Thus, when conventional osteotomies are performed carefully, using controlled, visualized cuts and preservation of the mucosa, the incremental benefit of a powered microsaw over manual instruments may be minimal.[4-6]

Another factor is the learning curve and operator experience. All surgeries in this trial were performed by an experienced surgical team proficient in both techniques. The microsaw was used in a precise manner, but it is plausible that any potential benefit of the microsaw might only manifest in less experienced hands, or conversely, that its benefit is more pronounced in very difficult cases (such as extremely thick nasal bones) which were not a distinct subset in this sample. Moreover, the magnitude of difference in trauma between the 2 techniques might simply be too small to result in clinically detectable differences in edema or pain in a sample of 60 patients. If both methods cause only mild-to-moderate trauma, the postoperative recovery will be similar. This interpretation aligns with the notion that gentle tissue handling and surgical finesse are paramount. Consistent with shared surgical practice patterns and intraoperative observations, the authors prioritized minimizing periosteal stripping, performing osteotomy cuts under direct vision when feasible, and preserving the mucosal lining of the nasal bones to potentially reduce postoperative bruising and swelling.[19,20] In this series, the authors took these precautions in both groups. For example, in Group 1, the authors still used a guarded saw for the transverse osteotomy (rather than a purely blind fracturing), which may have mitigated the trauma typically associated with conventional osteotomies. This likely contributed to the comparable outcomes. In essence, the surgical technique and delicacy might outweigh the choice of instrument when both are used properly.

The finding that pain scores were no different between the 2 groups is also noteworthy. One might assume that a powered device could induce less pain by causing less periosteal trauma.[21] However, pain in septorhinoplasty can stem from multiple sources—osteotomy-related pain, intranasal packing or splints, swelling and pressure, etc.[22] By day 3 and certainly by day 7, pain was low in both groups. Adequate analgesia and the natural healing process likely overshadow any subtle differences in pain generation between the techniques.[23] This result echoes some reports from piezo studies: while some found reduced pain with piezo, others did not report a significant pain difference despite less swelling, indicating pain perception is multifactorial.[4,8]

Patient satisfaction at 1 week post-op was moderate in both groups and statistically the same. This outcome is understandable because, around the first postoperative week, many protocols still involve external splinting and/or intranasal splints, and intranasal splints in particular have been associated with higher early symptom burden (e.g., pain, headache, obstruction) in the immediate postoperative visits.[24] Moreover, postoperative satisfaction is closely linked to the extent to which postoperative outcomes meet preoperative expectations, which may be especially relevant in the early period when final aesthetic results are not yet apparent.[25] The data suggest that using a microsaw did not make patients markedly happier or more comfortable in that first week compared to the conventional method. It is possible that patient satisfaction might diverge later (e.g., at 6 months), as longer-term satisfaction is more strongly influenced by aesthetic/functional outcome appraisal over time rather than early postoperative comfort alone.[1,26] For early recovery, ensuring adequate pain control and structured expectation management/counseling may be more critical than the choice of osteotomy tool.[23,25]

Limitations

This study has some limitations that must be acknowledged. First, the sample size (n = 60), while adequate to detect moderate differences, may not have been powered to detect very subtle differences between techniques. A type II error (false negative) is possible if the microsaw confers a small advantage that requires a larger sample to demonstrate. Second, the assessment of edema and ecchymosis was limited to postoperative days 3 and 7. The authors did not include a day 1 assessment of bruising/swelling because the immediate post-op period had confounding factors (dressings, varying timing of observation) and many patients still had their eyes partially covered with tape or bandages in the first 24 hours, making standardized evaluation difficult. It is conceivable that any difference between techniques might be more evident on the first or second postoperative day, immediately after surgery, before substantial resolution occurs. By day 3, some initial difference could have already narrowed. Third, the study was single-center and all surgeries were performed by the same team; while this ensures consistency, it may limit generalizability. Different surgeons might produce different amounts of trauma with the same tools, and thus, results could vary. Fourth, we only evaluated short-term outcomes for patient comfort. The authors did not assess long-term outcomes such as final aesthetic results or functional outcomes (e.g., whether one method leads to smoother nasal bones or fewer postoperative deformities). It is possible that microsaw osteotomies could have benefits in terms of precision that manifest in improved long-term contour or reduced need for revision, which were outside the scope of early postoperative focus.

Despite these limitations, the study was strengthened by its prospective randomized design and the use of blinded observers for outcome assessment, which reduces bias. To this knowledge, this is one of the first studies to directly compare microsaw and conventional osteotomy techniques in rhinoplasty in a controlled manner, including evaluation of patient-centric outcomes like comfort and satisfaction. The novelty of examining a relatively under-studied tool

(microsaw) in rhinoplasty adds value, especially since the literature so far has been dominated by piezoelectric device research. The findings contribute to the evidence base suggesting that new technology must be critically evaluated for true clinical benefit.

Conventional and microsaw osteotomy techniques produced comparable early postoperative outcomes after septorhinoplasty. Edema, ecchymosis, and pain decreased similarly over the first week, and patient satisfaction at postoperative day 7 did not differ between groups. These findings suggest that, when performed with meticulous technique, an oscillating microsaw does not provide a measurable advantage in early patient comfort over standard instruments. Accordingly, osteotomy tool selection may be guided by surgeon preference, device availability, and case-specific factors. Future multicenter studies with larger samples and longer follow-up, including objective assessment of osteotomy precision and long-term contour/healing, are warranted to determine whether microsaw use offers benefits beyond the immediate postoperative period.

Data Availability Statement: *The data that support the findings of this study are available on request from the corresponding author.*

Artificial Intelligence Usage Statement: *The authors declared that no Artificial Intelligence tool was used in the preparation of the manuscript.*

Ethics Committee Approval: *Ethical committee approval was received from the Ethics Committee of Van Yüzüncü Yıl University (Approval No.: 07, Date: April 17, 2019).*

Informed Consent: *Written informed consent was obtained from all participants before enrollment in the study.*

Peer-review: *Externally peer-reviewed.*

Author Contributions: *Concept – S.R.; A.T.; Design – S.R.; U.D.; Y.E.T.; Supervision – A.T.; Resources – A.T.; S.R.; Materials – U.D.; Y.E.T.; Data Collection and/or Processing – U.D.; Y.E.T.; S.R.; Analysis and/or Interpretation – S.R.; Y.E.T.; A.T.; Literature Search – U.D.; Y.E.T.; Writing – S.R.; Y.E.T.; A.T.; Critical Review – A.T.; S.R.; U.D.*

Declaration of Interests: *The authors have no conflict of interest to declare.*

Funding: *The authors declared that this study has received no financial support.*

References

1. Kemal Ö, Tahir E, Kavaz E, et al. Impact of functional and aesthetic factors on patient satisfaction in septorhinoplasty. *Turk Arch Otorhinolaryngol*. 2022;60(1):36-41. [CrossRef]
2. Elsayed M, Alghamdi AS, Khan M, et al. Causes, prevention, and correction of complications of primary and revision septorhinoplasty. *Cureus*. 2021;13(12):e20557. [CrossRef]
3. Wu TJ, Huang YL, Kang YN, et al. Comparing the efficacy of different steroids for rhinoplasty: a systematic review and network meta-analysis of randomized controlled trials. *J Plast Reconstr Aesthet Surg*. 2023;84:121-131. [CrossRef]
4. Kisel J, Khatib M, Cavale N. A comparison between piezosurgery and conventional osteotomies in rhinoplasty on post-operative oedema and ecchymosis: a systematic review. *Aesthet Plast Surg*. 2023;47(3):1144-1154. [CrossRef]
5. Khajuria A, Krzak AM, Reddy RK, et al. Piezoelectric Osteotomy versus Conventional Osteotomy in Rhinoplasty: a Systematic Review and Meta-analysis. *Plast Reconstr Surg Glob Open*. 2022;10(11):e4673. [CrossRef]
6. Albazee E, Khatib A, Makhseed A, et al. Methods of lateral osteotomy in rhinoplasty: an updated systematic review and meta-analysis of randomised controlled trials. *Clin Otolaryngol*. 2025;51(2):233-245. [CrossRef]
7. Taşkın Ü, Batmaz T, Erdil M, et al. The comparison of edema and ecchymosis after piezoelectric and conventional osteotomy in rhinoplasty. *Eur Arch Otorhinolaryngol*. 2017;274(2):861-865. [CrossRef]
8. Safia A, Abd Elhadi U, Farhat R, et al. Is piezosurgery associated with improved patient outcomes compared to conventional osteotomy in rhinoplasty? A systematic review and meta-analysis of RCTs. *J Clin Med*. 2024;13(13):3635. [CrossRef]
9. Ilhan AE, Cengiz B, Caypinar Eser B. Double-blind comparison of ultrasonic and conventional osteotomy in terms of early postoperative edema and ecchymosis. *Aesthet Surg J*. 2016;36(4):390-401. [CrossRef]
10. Koçak I, Doğan R, Gökler O. A comparison of piezosurgery with conventional techniques for internal osteotomy. *Eur Arch Otorhinolaryngol*. 2017;274(6):2483-2491. [CrossRef]
11. Mirza AA, Alandejani TA, Al-Sayed AA. Piezosurgery versus conventional osteotomy in rhinoplasty: A systematic review and meta-analysis. *Laryngoscope*. 2020;130(5):1158-1165. [CrossRef]
12. Demirbilek N, Evren C. Is piezoelectric surgery really harmless to soft tissue? *J Craniofac Surg*. 2019;30(7):1966-1969. [CrossRef]
13. Pamuk G, Pamuk AE, Kandemir S. Powered micro-saw versus conventional osteotome for septorhinoplasty: a prospective, double-blind, comparative study. *Aesthet Plast Surg*. 2023;47(3):1133-1141. [CrossRef]
14. Avsar Y. The oscillating micro-saw: a safe and pliable instrument for transverse osteotomy in rhinoplasty. *Aesthet Surg J*. 2012;32(6):700-708. [CrossRef]
15. Bayrakci E, Aricigil M, Eryilmaz MA, et al. Edema, Ecchymosis, and Pain: classic versus Electric Micro-Saw Osteotomy. *Facial Plast Surg*. 2025;42(1):11-16. [CrossRef]
16. Fallahi HR, Keyhan SO, Fattahi T, et al. Comparison of piezosurgery and conventional osteotomy post rhinoplasty morbidities: a double-blind randomized controlled trial. *J Oral Maxillofac Surg*. 2019;77(5):1050-1055. [CrossRef]
17. Barrera JE. Application of ultrasonic piezoelectric technology for rhinoplasty. *Facial Plast Surg Aesthet Med*. 2022;24(3):165-167. [CrossRef]
18. Baris K, Hendek M, Olgun HE. Thermal analysis of a dry cooling method in a dental implant drilling procedure: an in vitro randomized study. *BMC Oral Health*. 2025;25(1):1274. [CrossRef]
19. Kim JS, Kim SH, Lee H, et al. Effects of periosteal elevation before lateral osteotomy in rhinoplasty: a meta-analysis of randomized controlled trials. *Clin Exp Otorhinolaryngol*. 2020;13(3):268-273. [CrossRef]
20. Altunay ZO, Onerci M. Endoscopic lateral osteotomy in rhinoplasty. *J Craniofac Surg*. 2021;32(2):609-611. [CrossRef]
21. Kim DH, Park JB, Kim SW, et al. Effect of infraorbital and/or infratrochlear nerve Blocks on postoperative Care in Patients with Septorhinoplasty: a Meta-Analysis. *Medicina (Kaunas)*. 2023;59(9):1659. [CrossRef]
22. Abi Zeid Daou C, Zaytoun G, Hadi U, et al. The use of different intranasal splints Doyle splints versus Reuter bivalve splints versus no splints in primary septal surgeries: a randomised clinical trial looking at morbidity. *Clin Otolaryngol*. 2024;49(1):87-93. [CrossRef]
23. Shafiee A, Arabzadeh Bahri R, Teymouri Athar MM, et al. Pain management following septorhinoplasty surgery: evidence from a systematic review. *Eur Arch Otorhinolaryngol*. 2023;280(9):3931-3952. [CrossRef]
24. Rasti M, Talebian E. Evaluation of clinical outcomes and satisfaction of rhinoplasty with or without Smasectomy with the aim of thinning the nasal tip in patients with thick nasal skin. *World J Plast Surg*. 2022;11(2):117-128. [CrossRef]
25. Avcu M, Metin M. Evaluation of the relationship between patient expectation, patient expectation coverage rates and patient satisfaction in open primary septorhinoplasty surgery: a prospective randomized study. *Eur Arch Otorhinolaryngol*. 2021;278(7):2337-2346. [CrossRef]
26. Luong KP, Slijper HP, Stubenitsky B, et al. Changes in patient-reported satisfaction and quality-of-life 6 months after rhinoplasty. *J Plast Reconstr Aesthet Surg*. 2024;91:325-334. [CrossRef]